

CASE REPORT

Open Access

# Membranous nephropathy with acquired factor V inhibitor: a case report

Shinji Kitamura<sup>1\*</sup>, Mahito Misawa<sup>2</sup>, Sayaka Namba<sup>1</sup>, Kenji Tsuji<sup>1</sup>, Rikako Torigoe<sup>3</sup>, Midori Shima<sup>4</sup> and Hirofumi Makino<sup>1</sup>

## Abstract

**Background:** Membranous nephropathy is one of the most common causes of nephrotic syndrome in adults. In contrast, acquired factor V inhibitor is a rare bleeding disorder.

**Case presentation:** A 62-year-old Asian man with a history of cerebral hemorrhage, purpura, eosinophilia and hyper immunoglobulin E syndrome developed proteinuria. The bleeding disorder was diagnosed with acquired factor V inhibitors. A renal biopsy revealed that he suffered from membranous nephropathy with glomerular endothelial damage which is reported to be involved in another factor disorder. After the steroid administration, the coagulation test and proteinuria were improved.

**Conclusions:** The presence of factor V inhibitors may have been involved in the development of membranous nephropathy.

## Background

Membranous nephropathy (MN) is one of the most common causes of nephrotic syndrome in adults. MN occurs as a primary or secondary renal disease. Secondary MN occurs as a result of autoimmune diseases, infections and malignancies. In contrast, acquired factor V (FV) inhibitor is a rare bleeding disorder that is known to be difficult for physicians to treat because of limited knowledge and its uncertain relationship with autoimmune disease. Here we suggest a relationship between MN and FV inhibitors.

## Case presentation

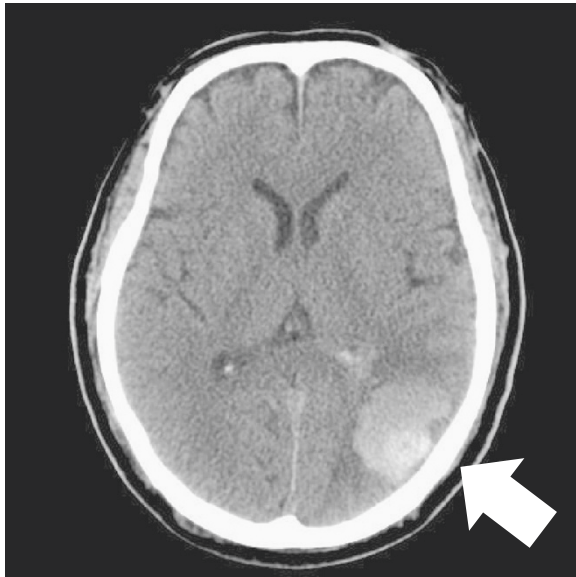A 62-year-old Asian man consulted a doctor because of asthmatoïd wheeze, anarthria, purpura and gait disturbance. He has no history of hypertension. He pointed out proteinuria for the first time two months ago before the consultation. He was diagnosed with a cerebral hemorrhage following a computerized tomography scan (Figure 1). His laboratory findings revealed that his serum creatinine concentration was 0.66 mg/dl, his serum IgE

concentration was 18230 IU/ml (normal: <170 IU/ml), and his eosinophil count was 18900/ $\mu$ l. His urinary analysis revealed 1.61 g/gCr of proteinuria. Coagulation tests revealed a prolonged activated partial thromboplastin time at 61.2 seconds and a prothrombin time of 25.5 seconds. In addition, FV activity alone severely decreased to 4.4% of normal, and an FV inhibitor was present at a titer of 2.5 BU/ml, suggesting the presence of antibody-mediated circulating inhibitors specific for FV (Table 1). The patient was diagnosed with a cerebral hemorrhage, eosinophilia, hyper IgE syndrome and acquired FV inhibitors. Steroid therapy with prednisolone (1 mg/kg) for the treatment of purpura and acquired FV inhibitors was administered. Treatment with steroid led to the improvement of his clinical symptoms including purpura, normalization of the coagulation tests, and disappearance of eosinophilia. To confirm the diagnosis of proteinuria, we performed a renal biopsy. Fine granular depositions were observed at the subepithelial layer in the glomerulus upon IgG fluorescent staining (Figure 2). Spike formations were partially observed at the subepithelial layer upon Periodic acid-methenamine-silver (PAM) staining (Figure 3). An impaired lamina rara layer and endothelial cell swelling and detachment were observed with high-density deposits at the lamina rara externa upon electron microscopic analysis (Figure 4, Additional file 1: Figure S1 and

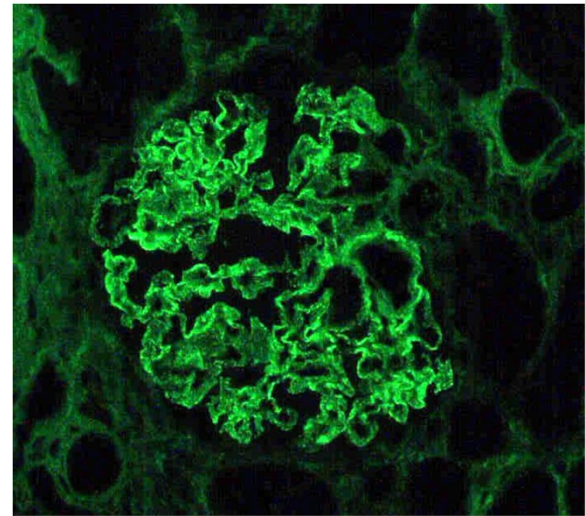
\* Correspondence: s-kita@md.okayama-u.ac.jp

<sup>1</sup>Department of Medicine and Clinical Science, Okayama University Graduate School of Medicine, Dentistry and Pharmaceutical Sciences, 2-5-1 Shikata-cho, Okayama 700-8558, Japan

Full list of author information is available at the end of the article



**Figure 1** Left cerebral hemorrhage (arrow) image on computerized tomography.



**Figure 2** Immunoglobulin G fluorescent staining analysis revealed that fine granular depositions were observed at subepithelial layer in glomerulus. (Magnification: 400X).

Additional file 2: Figure S2). We determined that the patient had developed MN with glomerular endothelial cell damage. After the administration of steroid therapy, the proteinuria improved gradually.

### Discussion

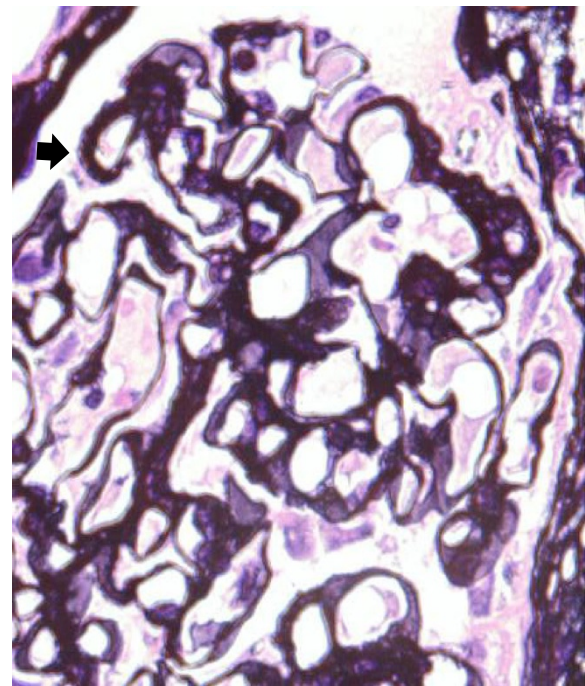
MN is caused by immune complex localization in the subepithelial zone of glomerular capillaries. Beck *et al.* reported that M-type phospholipase A<sub>2</sub> receptor (PLA<sub>2</sub>R) is a target antigen with idiopathic MN [1]. The Anti- PLA<sub>2</sub>R autoantibodies in serum samples from patients with idiopathic MN were predominantly of IgG4 subclass, which is the predominant immunoglobulin subclass seen in glomerular deposits of patients with MN. However, the Anti- PLA<sub>2</sub>R autoantibodies were not exclusively found in secondary MN. In renal biopsy of this patient, we could not observe the deposits of IgG4 subclass (Additional file 3: Figure S3). We could

not find any causes of secondary MN such as malignancy, infections or drugs. These results suggested that the MN in this patient may be involved other immune disorders.

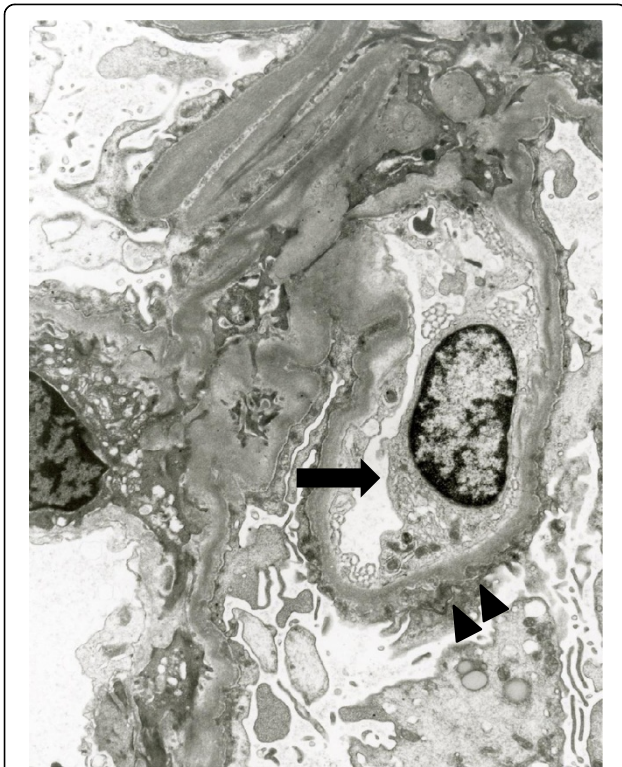
On the other hand, there have been some reports of acquired factor inhibitors complicated by nephrotic syndrome [2-4]. In addition, there have been reports that factor VIII-related antigen and tissue plasminogen activator

**Table 1** Laboratory analysis data of coagulation time and coagulation factors

Coagulation time	Time (sec)
Prothrombin time	25.5
Activated partial thromboplastin time	61.2
Coagulation factors	Activity (%)
Factor II	93.0
Factor V	4.4
Factor VIII	77.0
Factor IX	168.4
Factor X	93.0



**Figure 3** Periodic acid-methenamine-silver staining analysis showed that spike formations (arrow) were observed partially at the subepithelial layer in the glomerulus. (Magnification: 400X).



**Figure 4** Electron microscopic analysis demonstrated the swelling of the endothelial cell (arrow), the damage of lamina rara layer and electron dense deposit at the subepithelium (arrow head). (Magnification: 8050X).

may be involved in the glomerular endothelial damage in another factor disorder [5]. There is a possibility that coagulopathies may be related to the occurrence of renal disorders with glomerular endothelial cell damages. In this patient, we observed dense subepithelial deposition and the detachment of endothelial cells in the glomerulus upon electron microscopic analysis. It may be suggested that the characteristic finding of membranous nephropathy with acquired factor inhibitors is the presence of damage of the glomerular endothelial cells and lamina rara layer, with high-density deposits at the subepithelium in the glomerulus. Frigui *et al.* reported that the eosinophils are associated with MN [6]. Renal disorders with eosinophils were caused by several diseases such as drugs, cholesterol embolization, immunoallergic responses *et al.* [7]. Giudicelli *et al.* described that most secondary renal disorders in hyperphils are usually due to an immuno-allergic process leading to deposit of immune complexes in glomeruli. Taken together, we reported that membranous nephropathy complicated with factor V inhibitor. The presence of FV inhibitors should be taken into consideration when patients are diagnosed with nephrotic syndrome and MN by renal biopsy because there is some possibility that the FV inhibitors can lead to serious bleeding complications.

## Conclusions

We reported a case of membranous nephropathy with acquired factor V inhibitor. The renal pathology revealed the presence of damage of the glomerular endothelial cells and lamina rara layer, with high-density deposits at the subepithelium in the glomerulus. It is important that membranous nephropathy may be complicated with acquired factor V inhibitor if the pathology is observed.

## Consent

Written informed consent was obtained from the patient for publication of this Case Report and any accompanying images. A copy of the written consent is available for review by the Editor-in-chief of this journal.

## Additional files

**Additional file 1: Figure S1.** Electron microscopic analysis demonstrating the detachment of endothelial cells (arrowhead), damage to the lamina rara layer and electron-dense deposits at the subepithelium (arrow). (Magnification: 8050X).

**Additional file 2: Figure S2.** Electron microscopic analysis demonstrating the electron-dense deposits at the subepithelium (arrow). (Magnification: 6900X).

**Additional file 3: Figure S3.** Immunohistochemistry analysis demonstrating not for the immunoglobulin G4 deposits but for immunoglobulin G deposits in the glomeruli of the patient. deposits at the subepithelium (arrow). (Magnification: 400X).

## Competing interests

The authors declare that they have no competing interests.

## Authors' contribution

SK, MM, RT and SN were the treating physicians of the patient. MS evaluated the laboratory analysis data of coagulation time and coagulation factors. SK, SN, KT and HM performed the evaluation of the renal biopsy. All authors participated in the discussion of the manuscript and approved the final version.

## Author details

<sup>1</sup>Department of Medicine and Clinical Science, Okayama University Graduate School of Medicine, Dentistry and Pharmaceutical Sciences, 2-5-1 Shikata-cho, Okayama 700-8558, Japan. <sup>2</sup>Department of Internal Medicine, Aiko Central Hospital, Aiko, Japan. <sup>3</sup>Department of dermatology, Aiko Central Hospital, Aiko, Japan. <sup>4</sup>Department of Pediatrics, Nara Medical University, Kashihara, Japan.

Received: 7 June 2013 Accepted: 18 December 2013

Published: 21 December 2013

## References

1. Beck LH Jr, Bonegio RG, Lambeau G, Beck DM, Powell DW, Cummins TD, Klein JB, Salant DJ: **M-type phospholipase A2 receptor as target antigen in idiopathic membranous nephropathy.** *N Engl J Med* 2009, **361**:11–21.
2. Takahashi H, Fuse I, Abe T, Yoshino N, Aizawa Y: **Acquired factor V inhibitor complicated by Hashimoto's thyroiditis, primary biliary cirrhosis and membranous nephropathy.** *Blood Coagul Fibrinolysis* 2003, **14**:87–93.
3. Verghese P, Darrow S, Kurth MH, Reed RC, Kim Y, Kearney S: **Successful management of factor IX inhibitor-associated nephrotic syndrome in a hemophilia B patient.** *Pediatr Nephrol* 2013, **28**:823–826.
4. Chang H, Chen YM, Dunn P: **Factor VIII inhibitor associated with nephrotic syndrome.** *Haemophilia* 2007, **13**:766.

5. Imai C, Kakihara T, Iwabuchi H, Tanaka A, Furukawa T, Uchiyama M: **Glomerular vasculopathy after unrelated cord blood transplantation.** *Pediatr Nephrol* 2003, **18**:399–402.
6. Frigui M, Hmida MB, Jallouli M, Kechaou M, Frikha F, Bahloul Z: **Membranous glomerulopathy associated with idiopathic hypereosinophilic syndrome.** *Saudi J Kidney Dis Transpl* 2010, **21**:320–322.
7. Giudicelli CP, Didelot F, Duvic C, Desrame J, Herody M, Nedelec G: **Eosinophilia and renal pathology.** *Med Trop (Mars)*. 1998, **58**:477–481.

doi:10.1186/1756-0500-6-553

**Cite this article as:** Kitamura *et al.*: Membranous nephropathy with acquired factor V inhibitor: a case report. *BMC Research Notes* 2013 **6**:553.

**Submit your next manuscript to BioMed Central  
and take full advantage of:**

- Convenient online submission
- Thorough peer review
- No space constraints or color figure charges
- Immediate publication on acceptance
- Inclusion in PubMed, CAS, Scopus and Google Scholar
- Research which is freely available for redistribution

Submit your manuscript at  
[www.biomedcentral.com/submit](http://www.biomedcentral.com/submit)

